

Safety evaluation of chloramine –T on ornamental zebra fish (*Danio rerio*) using LC50 calculation and organ pathology

Alidadi Soleimani T.¹; Sattari A.^{2*}; Kheirandish R.³; Sharifpour I.⁴

Received: February 2016

Accepted: October 2016

Abstract

The need of aquarists for proper and safe disinfection of fish with Chloramine-T (CL-T) necessitates toxic/pathologic examinations. This study assays toxicity level of CL-T and histopathologic changes of gills, liver, kidney and brain of treated zebrafish (*Danio rerio*). Groups of 10 Zebrafish were treated with 0 (control), 5, 10, 15, 30, 50, 100 and 200 mg/L of CL-T. Mortality was recorded at every 6 hours until 96h after the beginning of the treatment and lethal concentration for 50% of population (LC50 at 24h and 96h) was calculated. The histopathologic samples were taken from dying fish during the exposure period. Histopathological changes were not evident in organs of the control group. In the gills of treatment groups, congestion, edema, separation of epithelium of secondary lamella from basal membrane, fusion and hypertrophy of secondary lamella, telangiectasis and necrosis of lamella epithelium were observed. In the liver of treatment groups degenerative changes and necrosis of hepatocytes were visible. The kidney samples represented hydropic degeneration, necrosis, dilation of periglomerular urinary space and hyaline droplets in renal tubules in high concentration. The brain of treatment groups showed spongiosis and increase in glial cells. Severity of these lesions was related to the concentration of CL-T. LC50 24h for CL-T was 428.649 mg/L and LC50 96h was 11.044 mg/L which reveals the low level of toxicity for few hours of treatment. The concentrations below 15mg/L are reasonably safe and recommended for usage in *D. rerio* treatment during 24h of bath.

Keywords: Zebrafish, Chloramine - T, Histopathology , LC50

1- Student of Doctorate of Veterinary Medicine.

2- Department of Food Hygiene and Quality Control, Division of Aquatic Animal Health and Diseases, Faculty of Veterinary Medicine, Shahid Bahonar University of Kerman, Kerman, Iran.

3- Department of Pathobiology, Division of Pathology and Necropsy, Faculty of Veterinary Medicine, Shahid Bahonar University of Kerman, Kerman, Iran.

4- Department of Aquatic Animal Health & Disease, Iranian Fisheries Science Research Institute (IFSRI), Agricultural Research Education and Extension Organization (AREEO), P.O.Box: 13185-116, Tehran, Iran.

* Corresponding author's Email: amirsattari73@yahoo.com

Introduction

The natural microflora of water are capable of invading the skin and gill of fishes under stressful and unsuitable conditions such as climate change, low water quality, high stocking density, transportation, immune system deficiency and physiologic stresses like spawning and migration. Flavobacters such as *Flavobacterium columnarum* (agent of Columnaris disease) and *Flavobacterium branchiophilum* (bacterial gill disease, BGD) can cause high mortalities in great number of cultured fishes (Dorborrow *et al.*, 1998). A number of disinfectants have been offered and used to control these agents among which some are recognized as being damaging for the environment and human. Surface disinfection of fertilized fish eggs has been widely used in aquaculture to reduce or eliminate extra-ovum pathogens that may be released from brood fish during spawning. This is an integral step used by aquaculturists in an attempt to avoid maternal transmission. Iodine is the disinfectant of choice for salmonids and other species whereas chlorine is most often used with zebrafish. Most zebrafish research laboratories disinfect the embryos with chlorine with new introductions to a facility, and some use this procedure on a routine basis with each spawn. Common concentrations and doses used by most zebrafish laboratories are between 25–50 ppm for about 10 min (Westerfield, 2007; Harper and Lawrence, 2011).

Other than Chlorine another chlorinated compound; N-Sodium- N-Chloro-P- Toluenesulfonamide ($C_7H_7CINNAOS_3H_2O$, Chloramine – T, Halamid[®]) has been used as a disinfectant since the early 1900s in wide variety of industries ranging from hospitals to agricultural uses, and has been assumed to be effective against bacterial agents on fish gill and skin and infested monogenes and also some saprophytic fungi (Bullock *et al.*, 1991, Bowker and Erdhal 1998, Gaikawski *et al.*, 2008 and 2009). The good point of CL-T application compared with the antibiotics is the absence of drug resistance (Hankes and MS., 2002). For years chlorine has been used for urban and rural tap water disinfection. The concentration of chlorine required to successfully treat public water sources is high enough to be lethal to fish however it can be neutralized by chemical and physical remedies. In recent years, water treatment plants have increasingly turned to chloramines as an alternative to chlorine. Chloramines are a combination of ammonia with chlorine. Contrary to straight chlorine, which dissipates fairly quickly when exposed to air, chloramines remain in the water for longer disinfection of tap water. Since the special types of ornamental fish like Zebra, Guppy, Molly, Goldfish and Swordtail are produced, transported and distributed in high densities and in large scale, they suffer from many external microbial injuries and are assumed as agents of contamination spread and

must be efficiently disinfected (Personal communications). The local aquarists are recently interested in the use of CL-T to control the bacterial agents of fin, gill and tail rot in ornamental fish based on their experiences while to the knowledge of the authors no study has investigated the toxicity level of existing CL-T (Halamid[®]) and the remaining histopathological impacts on vital organs of mentioned fishes.

This study investigates the toxic effects of CL-T on gills, liver, kidney and brain of *Danio rerio* and calculates the LC50 of the population during 24 and 96h to meet the need for proper and safe disinfection and to make a clear and scientific protocol for usage in aquarium and culture systems.

Materials and methods

Fish

All exposure studies were conducted at the Aquatic Research Laboratory of the veterinary faculty at Shahid Bahonar University of Kerman. 80 Zebra fish (mean weight and length of 0.5gr and 2.46cm) were randomly dispersed among 8 aquaria filled with aerated well water (27°C, pH=7.6).

Exposure

After 10 days of acclimation to laboratory conditions (70L aquarium filled with 27°C of well water at the aquatic lab of veterinary faculty of Kerman University and feeding of once daily with Biomar[®] food) treatment groups of 0, 5, 10, 15, 30, 50, 100 and

200 mg/L of CL-T (Halamid[®], Lot No:0703681061 Axcentive Co., France) (10 fish per group). At 6, 12, 18, 24, 48, 72 and 96 h after beginning of the treatment, fish in each container were checked for behavioral observation and mortalities were recorded.

Examinations

The dying fish were separated and used for histopathologic examinations at any of observation points. If a group had no mortality until 24h, the pathology sampling was randomly performed from the fish of the group. After confirming death, the whole dead fish was fixed in 10% buffer formalin solution and passed the fixation and histotechnique process (Tissue processor, DS2080/H, Didsabz Co., Iran). The serial sectioning was performed using rotary microtome (Rotary4050, Slee Co., Germany) from the whole fish in order to achieve the 5µm sections of body inclusive of sections of required organs that were observed under light microscope after Hematoxylin and Eosin staining.

Statistics

The SPSS 19, Probit was used to analyze the mortality data and calculate the LC50 with the confidence limit of 95%.

Results

Mortality/LC50

No mortality was observed in control and treatment group 1 but in higher

concentrations, after 96h, mortality was considerable and in groups 5, 6 and 7 all fish were dead. No mortality was observed in treatments up to 15mg/L until 24h and 50mg/L of CL-T left only one dead fish during 24h (Table 1). The LC50 24h for CL-T in this study was calculated as 69.363 mg/L and LC50 96h was 11.044 mg/L.

Histopathology

Gills

The natural structure of primary and secondary lamella was observed in the control group. In the gills of treatment groups, in different concentrations, various changes including congestion, subepithelial space edema, separation of epithelium of secondary lamella from basal membrane, fusion and hypertrophy of secondary lamella, telangiectasis and necrosis of lamellar epithelium, were observed (Figs. 1, 2 and 3). The intensity of the lesions in different groups is shown in Table 2.

Liver

In the control group and treatment group 1, the liver was natural but

necrosis and degenerative lesions were observed in other groups. Severity of these lesions were related to the concentration of CL-T and increased in higher concentrations (Fig. 4).

Kidney

In the kidneys of control groups and treatment groups 1 and 2, no histopathological changes were evident but changes including hydropic degeneration, necrosis and dilation of periglomerular urinary space were observed in other groups. The severity of these lesions was increased in higher concentrations. Also in some sections in groups 6 and 7, hyaline droplets within renal tubules were observed (Figs. 5 and 6).

Brain

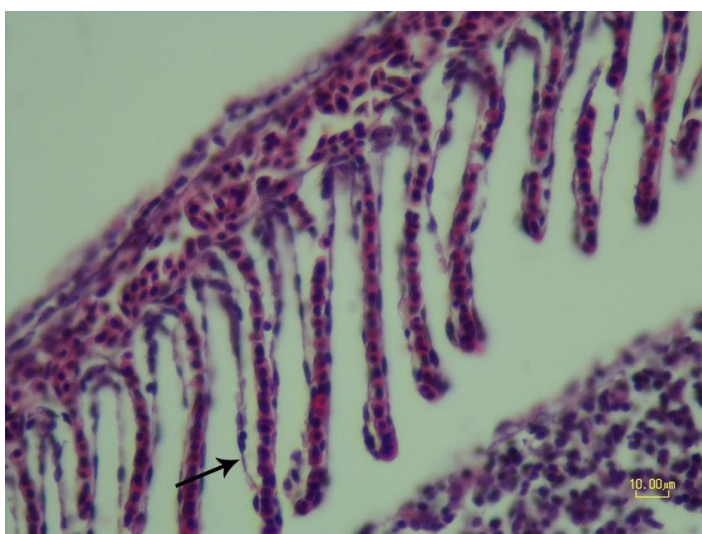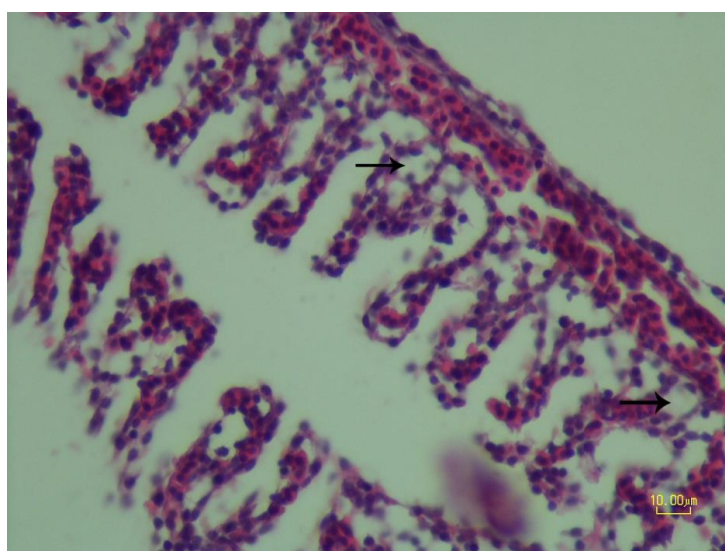
In the control group and treatment groups 1 and 2 the brain was healthy and had natural structure but degrees of spongiosis and increasing in glial cells were observed in other groups. Severity of the lesions was related to the concentration of CL-T (Fig. 7).

Table 1: Mortality of zebrafish recorded at different concentrations of CL-T during 96h. treatment groups

	Concentration of CL-T (mg/L)	Mortality							
		6 h	12 h	18 h	24 h	48 h	72 h	96 h	total
control	0	-	-	-	-	-	-	-	-
1	5	-	-	-	-	-	-	-	-
2	10	-	-	-	-	-	3	6	9
3	15	-	-	-	-	3	1	5	9
4	30	1	1	-	-	-	4	2	8
5	50	-	-	1	-	7	-	2	10
6	100	-	4	2	3	1	-	-	10
7	200	1	4	5	-	-	-	-	10

Table 2: The grading of induced lesions in gills of zebrafish at different concentrations of CL-T. (mild +, moderate ++, severe +++).

Lesion	treatment groups						
	1	2	3	4	5	6	7
Congestion	+	++	++	++	++	++	++
Edema	+	++	+++	+++	+++	+++	+++
Separation of epithelium of secondary lamella	+	+	++	++	++	++	++
Hypertrophy of secondary lamellas	-	+	+	+	+	+	+
Necrosis of secondary lamellas	-	-	-	+	++	++	++
Telangiectasis	-	-	+	++	++	++	++
Fusion of secondary lamellas	+	++	++	++	+++	+++	+++

**Figure 1: Treatment group 1. gill. congestion and separation of secondary lamellar epithelium from basement membrane (arrow).****Figure 2: Treatment group 2. gill. secondary lamellar edema (arrow).**

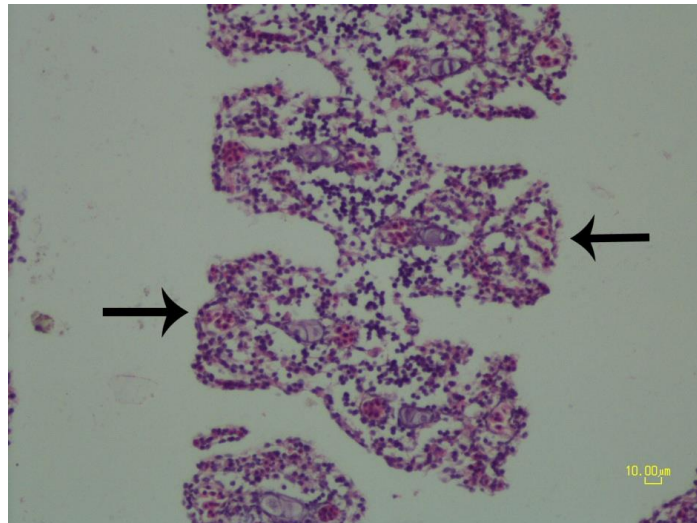


Figure 3: Treatment group 6. gill. secondary lamellas are fused (arrow) and clearly showed edema.

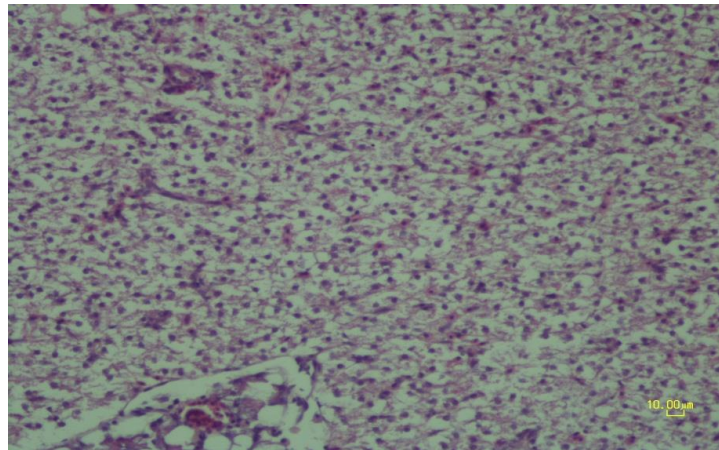


Figure 4: Treatment group 7. liver. severe hydropic degeneration and necrosis of hepatocytes.

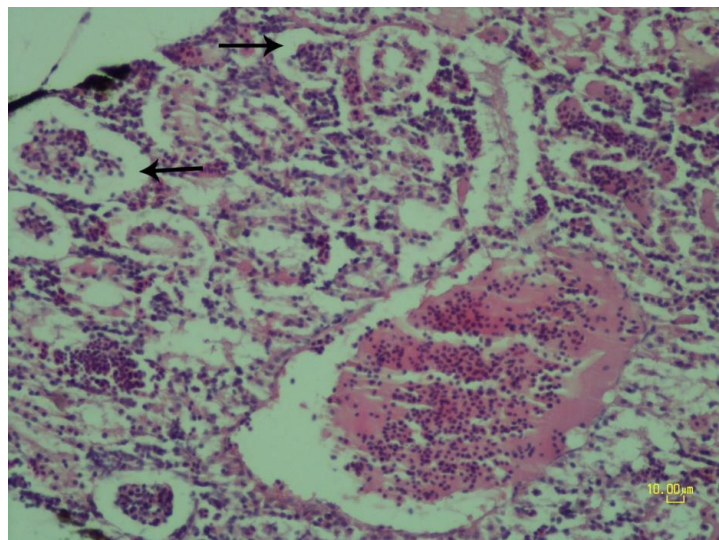


Figure 5: Treatment group 5. kidney. severe hydropic degeneration of renal tubular epithelium and dilation of periglomerular urinary space (arrow).

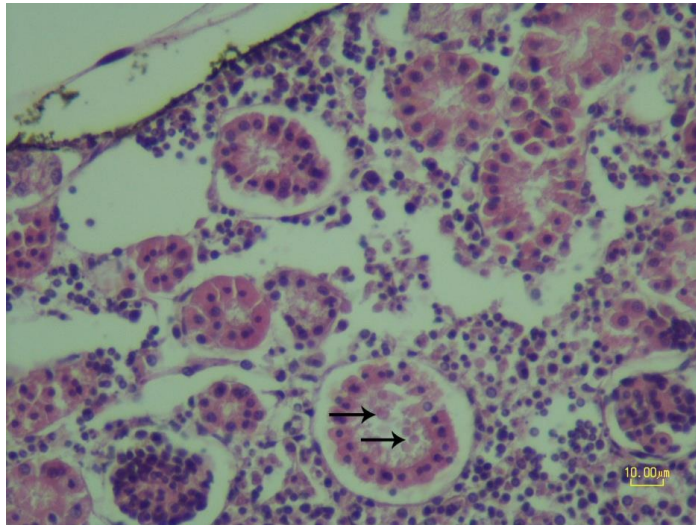


Figure 6: Treatment group 7. kidney. hyaline droplets in renal tubules (arrow).

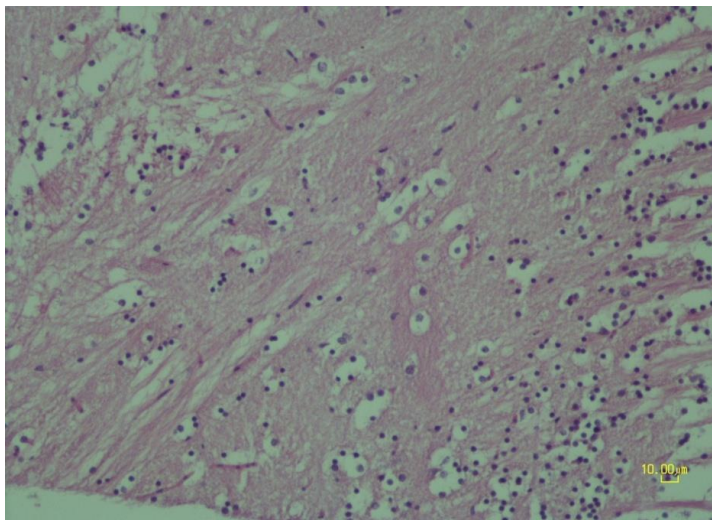


Figure 7: Treatment group 7. brain. spongiosis and increase in glial cells (arrow).

Discussion

Exposure of aquatic organisms to different levels of chloramine - T, may result in histological alternations in vital tissues such as gills, liver, kidney and brain. The result of this study revealed no histopathological changes in investigated organs of control and treated groups 1 and 2. In the gills of subsequent treatment groups (3 and further) congestion, edema, separation of epithelium of secondary lamella

from basal membrane, fusion and hypertrophy of secondary lamella, telangiectasis and necrosis of lamella epithelium were observed which can lead to physiological disorders and death of fish. Similarly some morphological changes in gill epithelia in Atlantic salmon, gold fish, rainbow trout, channel catfish and walleye have been associated with exposure to CL-T (Powell *et al.*, 1995; Sanchez *et al.*, 1997; Altinok, 2004; Powell and Harris,

2004; Gaikowski *et al.*, 2009). In the other treatment groups (3 and further) liver degenerative lesions and necrosis and kidney hydropic degeneration, necrosis, dilation of periglomerular urinary space and hyaline droplets in renal tubules (especially at the higher concentrations) were visible. The absence of serious lesions in lower concentrations is in accordance with the study of Gaikowski *et al.* (2009) who investigated the impacts of intermittent and frequent contact of Walleye and Channel catfish with CL-T. In the brain of the same treatment groups, spongiosis and increase in glial cells were observed.

The histopathological assessments of this work suggest positive relationships between the concentration of CL-T treatment and intensity of histological changes in different organs of gills, liver, kidney and brain.

Histopathological changes in the gills of fishes due to pesticides and other chemicals have been reported by authors (Mallatt 1985; Richmonds and Dutta, 1989). Since the gills are the primary route for the entry of chemicals and the liver is the main detoxifying organ (Dutta *et al.*, 1993), these are preferentially discussed here. The telangiectasis, rupture of the gill epithelium and epithelial necrosis are responses of the action of the CL-T. The noticed defense responses are excessive mucus secretion, lifting up of the epithelium and lamellar fusion. The lifting of the epithelium increases the distance through which the chemical

has to travel to reach the blood stream. Lamellar fusion diminishes the amount of vulnerable gill surface area and could be protective in this way (Mallatt, 1985). Gill necrosis might serve as a defensive mechanism leading to a decrease in the respiratory surface and an increase in the toxicant blood diffusion distance (Majeed *et al.*, 2014). The results of these alterations in gills could be understood as a defense mechanism against exposure to chemical agents rather than as an irreversible toxic effect.

Liver alterations may be useful as indicators of exposure to environmental stressors. About 85% of liver volume of teleosts is filled by hepatocytes. Stressful alterations may cause visible changes in the nucleus and/or cytoplasm. For instance irregular nuclear profiles with scalloped edges have been reported after fish were exposed to pesticides (Hacking *et al.*, 1978).

Hepatic lesions in liver tissue of fish exposed to cypermethrine were characterized as hydropic degeneration, necrosis, mononuclear cell infiltration and narrowing of sinusoids (Gulhan *et al.*, 2014)

After exposure to toxicants, coagulative necrosis resulting from stop of blood flow to an organ may occur. In this condition, the morphology of the organ is recognizable because cell membranes are maintained but the nuclei show clear areas centrally and chromatin clumps peripherally (karyolysis), fragmentation of nuclei

(karyorrhexis), or condensation of chromatin into a single dense dot (pyknosis). On the other hand, variation in staining features of cytoplasm is a signal exposure to lethal levels of toxicants. Lipid vacuoles that are distributed randomly are commonly observed in hepatocyte cytoplasm of affected organisms. Hepatic steatosis (lipid accumulation) in Zebrafish induced by long-term exposure to γ -Hexachlorocyclohexane was observed by Braunbeck *et al.* (1990). These researchers speculated that these obvious vesicles of lipid origin might be the morphological expression of blockage in the metabolism of hepatic triglycerides due to a defective synthesis of very low density lipoproteins which are involved in the transport and mobilization of hepatic triglycerides to extrahepatic tissues. Hypertrophy of hepatocytes is a closely-related condition that occurs under chronic toxicity (Myers *et al.*, 1987; Kent *et al.*, 1988). The istopathological changes because of an exposure to a toxicant may lead to a reduction in the functional efficiency of the liver leading to malfunctioning of several organ systems of the fishes (Ortiz *et al.*, 2003).

Since the kidney of fishes receives most part of postbranchial blood, renal lesions might be expected to be useful indicators of disinfectants and pesticides. Tubular degeneration and eosinophilic, proteinaceous, intratubular cast and hyaline droplets and an increase in the amount of hemosiderin

or melanin-like intratubular deposits in Catfish (*Ictalurus punctatus*), exposed to methyl mercury, were found by Kendall (1975). Wester and Canton (1986) found prominent glomerular hyalinosis as an indicator of renal toxicity, in medaka specimens exposed to a lindane isomer.

Kent *et al.* (2014) believed that Zebrafish embryos at 6 hours post fertilization (hpf) usually tolerated chlorine better than 24 hpf embryos exposed to similar conditions. Therefore they recommended chlorine treatments at close to 6 hpf which is not always possible, as often laboratories treat embryos after receiving them from other facilities. In this case, the duration or concentration of chlorine should be reduced. When using chlorine, Kent *et al.* (2014) suggested treating embryos for 5 min with unbuffered chlorine at 100 ppm to obtain minimal mortalities and malformations.

A protocol using buffered chlorine would be more precise, but this is not practical with large scale and frequent treatments as used in most zebrafish laboratories and hatcheries. However the germicidal capability of chlorine is profoundly affected by pH. Considering that water hardness and alkalinity directly influence the buffering capacity of water, chlorine at a given concentration will have different germicidal and toxic effects between laboratories. Hence, pH of egg disinfectant media should be monitored, at least periodically (Kent *et al.*, 2014).

The advantages of chloramines compared to the chlorine such as its stability and the continuity of its disinfecting effect made the aquarists and laboratory technicians more interested in the usage of chloramines instead of chlorine. In this study the authors realized that the LC50 a 24h and 96h of CL-T for Zebrafish were 69.363 mg/L and 11.044 mg/L, respectively and the mortality rates were very low (maximum two fish) during 24h at concentrations below 50mg/L. Also the absence of severe pathologic lesion in vital organs of treatment groups 1 and 2 and the fact that the mortality rate of some external infections with Flavobacters could be well controlled using 10-20 mg/L of CL-T (Altinok *et al.*, 2004), led the authors to the belief that concentrations below 15mg/L of chloramine –T are reasonably safe for usage in *D. rerio* treatment for at least 24 hours of bath which is quite a long period of safe disinfection compared to chlorine disinfection.

Acknowledgments

The authors are thankful to technical assistance of Mr. Hasanzade, technician of pathology lab of Veterinary Faculty of Kerman University. The project was financially supported by the Shahid Bahonar University of Kerman.

References

- Altinok, I., 2004.** Toxicity and therapeutic effect of chloramine-T for treating *flavobacterium*

columnare infection of gold fish. *Aquaculture*, 239, 47- 56.

Bowker , J. and Erdahl , D.E., 1998.

Observation on the efficacy of chloramine - T treatment to control mortality in a variety of salmonids, the progressive fish – culturist, 60, 63- 66.

Braunbeck, T., Storch, V. and Bresch, H., 1990.

Species-specific reaction of liver ultrastructure in zebrafish (*Brachydanio rerio*) and trout (*Salmo gairdneri*) after prolonged exposure to 4-chloroaniline. *Archives of Environmental Contamination and Toxicology*, 19(3), pp.405-418.

Bullock, G.L., Herman, R.L. and Waggy, G., 1991.

Hatchery efficacy trials with chloramine- T for control of bacterial gill disease. *Aquatic Animal Health*, 3, 48-50.

Dorborrow, R.M., Thune, R.L., Hawke, J.P. and Camus, A.C., 1998.

Columnaris disease, a bacterial infection caused by *flavobacterium columnare*, Southern Regional Culture Center Publication, 479P.

Dutta, H., Adhikari, S., Singh, N., Roy, P. and Munshi, J.S., 1993.

Histopathological change induced by malathion in the liver of a freshwater catfish, *Heteropneustes fossilis* (Bloch). *Bulletin of Environmental Contamination and Toxicology*, 51 (6), 895-900.

Gaikowski, M.P., Larson, W.J., Gingrich, W.H., 2008.

Survival of cool and warm fresh water fish

- following chloramine -T exposure. *Aquaculture*, 275, 20- 25.
- Gaikowski, M.P., Densmore, C.L. and Blazer, V.S., 2009.** Histopathology of repeated intermittent exposure of chloramine - T to walleye (*Sander vitreum*) and (*Ictalurus punctatus*) channel cat fish. *Aquaculture*, 287, 28- 34.
- Gulhan, M.F., Talas, Z.S., Erdogan, K. and Orun, I., 2014.** The effects of propolis on gill, liver, muscle tissues of rainbow trout (*Oncorhynchus mykiss*) exposed to various concentrations of cypermethrin. *Iranian Journal of Fisheries Sciences*, 13(3), pp. 684-701.
- Hacking, M., Budd, J. and Hodson, K., 1978.** The ultrastructure of the liver of the rainbow trout: normal structure and modifications after chronic administration of a polychlorinated biphenyl Aroclor 1254. *Canadian Journal of Zoology*, 56 (3), 477-491.
- Haneke, K.E., 2002.** Toxicological Summary for Chloramine-T [127-65-1] and p-Toluenesulfonamide [70-55-3]. ([http://ntp-server.niehs.nih.gov/ntp/htdocs/Chem_Background/ExSumPdf/Chloramine T.pdf](http://ntp-server.niehs.nih.gov/ntp/htdocs/Chem_Background/ExSumPdf/Chloramine_T.pdf)), Integrated Laboratory Systems, 68P.
- Harris, J.O., Powell, M.D., Attard, M. and Green, T.J., 2004.** Efficacy of chloramine-T as a treatment for amoebic gill disease (AGD) in marine Atlantic salmon (*Salmo salar* L.). *Aquaculture research*, 35(15), pp. 1448-1456.
- Kendall, M.W., 1975.** Acute effects of methyl mercury toxicity in channel catfish (*Ictalurus punctatus*) kidney. *Bulletin of Environmental Contamination and Toxicology*, 13 (5), 570-578.
- Kent, M.L., Buchner, C., Barton, C. and Tanguay, R.L., 2014.** Toxicity of chlorine to zebrafish embryos. *Diseases of Aquatic Organisms*, 107(3), 235P.
- Majeed, S.A., Nambi, K.S.N., Taju, G., Babu, V.S., Farook, M.A. and Hameed, A.S., 2014.** Development and characterization of a new gill cell line from air breathing fish *Channa striatus* (Bloch 1793) and its application in toxicology: direct comparison to the acute fish toxicity. *Chemosphere*, 96, pp. 89-98.
- Mallatt, J., 1985.** Fish gill structural changes induced by toxicants and other irritants: a statistical review. *Canadian Journal of Fisheries and Aquatic Sciences*, 42 (4), 630-648.
- Ortiz, J.B., González de Canales, M.L. and Sarasquete, C., 2003.** Histopathological changes induced by lindane (?-HCH) in various organs of fishes. *Scientia Marina*, 67 (1), 53-61.
- Powell, M.D., Wright, G.M. and Speare, D.J., 1995.** Morphological changes in rainbow trout (*Oncorhynchus mykiss*) gill epithelia following repeated intermittent exposure to chloramine -T.

Canadian Journal of Zoology, 73, 154-165.

Richmonds, C. and Dutta, H. ,1989.

Histopathological changes induced by malathion in the gills of blue gill *Lepomis macrochirus*. *Bulletin of Environmental Contamination and Toxicology*, 43 (1),123-130.

Sanchez, G., Speare, D.J., Macnair, N. and Johnson, G.1997.

Effect of prophylactic chloramine - T treatment on growth performance and condition indices for rainbow trout, *Aquatic Animal Health*, 278-284.

Spence, R., Gerlach, G., Lawrence, C. and Smith, C., 2008. The behavioral and ecology of the zebra fish, *Danio rerio*, *Biological Reviews*, 10, 1-36.

Wester, P. and Canton, J., 1986. Histopathological study of *Oryzias latipes* (medaka) after long-term β -hexachlorocyclohexane exposure. *Aquatic Toxicology*, 9 (1), 21-45.

Westerfield, M., 2007. The Zebrafish Book: A Guide for the Laboratory Use of Zebrafish *Danio* ("Brachydanio Rerio"). University of Oregon.