

Sex steroid levels, reproductive indices and histological examination of gonads in adult male and female Caspian shemaya, *Alburnus chalcoides*

Pouresmaeilian M.¹; Khara H.^{2*}; Ahmadnezhad M.³

Received: January 2016

Accepted: August 2016

Abstract

Reproductive status of *Alburnus chalcoides* adults from Anzali Wetland was investigated by histological examination of gonads, assessment of sex steroids (i.e. Progesterone (P), Estradiol-17 β (E2), Testosterone (T)) and reproductive indices (i.e. absolute fecundity, oocyte diameter, hepatosomatic index (%HSI) and gonadosomatic index (%GSI)). Totally, 42 females and 16 males were captured during March to May 2014 by gill net and divided into two age groups including 2 year olds and 3 year olds. In each age group, fish were classified into two groups depending on maturation stage i.e. matured and maturing fish. According to the results obtained, in each age group, there were no significant differences between matured and maturing males and females in terms of absolute fecundity ($p>0.05$). In each age group, oocyte diameter was higher in matured fish than in maturing individuals ($p<0.05$). In 2 year old males and In 3 year old females, higher HSI values were recorded in maturing fish compared to matured fish. In females, the plasma levels of E2, T as well as P were significantly higher and lower in maturing fish and matured individual, respectively. In males, only plasma T was higher in matured fish compared to maturing fish and other assayed steroids did not show significant differences. Also, the histological examination of gonads from 10 males and females showed that all fish were in the final maturation stages.

Keywords: Sex steroid, Reproductive indices, Histology, *Alburnus chalcoides*

1-Young Researchers and Elite Club, Lahijan Branch, Islamic Azad University, Lahijan, Iran, P. O. Box: 1616

2-Department of Fisheries, Lahijan Branch, Islamic Azad University, Lahijan, Iran, P. O. Box: 1616

3-Inland Waters Aquaculture Research Center, Iranian Fisheries Sciences Research Institute, Agricultural Research, Education and Extension Organization (AREEO), Bandar Anzali, Iran, P. O. Box: 61

*Corresponding author's Email: h.khara1974@yahoo.com

Introduction

Knowledge on reproduction properties of commercial fish species in nature is necessary for the management and control of their reproduction in captive conditions. The Caspian shemaya *Alburnus chalcoides* is widely distributed in the Black, Caspian and Aral Seas. Populations of this species occur mainly in the mostly western to southern coast of the Caspian Sea and supports local subsistence fishery (Tarkan *et al.*, 2005; Falahatkar *et al.*, 2015). Recently, because of damming of the rivers, over fishing during the spawning season and deterioration of its spawning grounds in the rivers and streams, this species is considered to be vulnerable to endangered in the south Caspian basin (Kiabi *et al.*, 1999; Naderi and Abdoli, 2004; Mostafavi H. 2007). In this basin, its spawning grounds range from the Atrak River (southeast) to the Aras River (southwest), being found mainly in the rivers of central parts of the basin. Reproduction of Caspian shemaya in captive conditions of a hatchery could be an appropriate way to produce juveniles for restocking programs and aquaculture goals. Nevertheless, access to biotechnical methods of propagation and rearing is dependent on level of our knowledge about its reproductive properties in nature. Several studies have presented data about the reproductive properties of commercial fish with investigation of gonad histology and assessment of plasma sex steroids (Reviewed by Mylonas *et al.*, 2010). In the present study, we

investigated the reproductive status of Caspian shemaya adults from Anzali Wetland by histological examination of gonads, assessment of sex steroids (P, E2 and T) and reproductive indices (i.e. absolute fecundity, oocyte diameter, %HSI) and %GSI). The Anzali Wetland is a very important and vital wetland on the southern coasts of the Caspian Sea in Northern Iran This study can enhance information about the reproductive properties of Caspian shemaya and help to collect information for propagation and rearing of this valuable species in hatcheries.

Materials and methods

Fish

Adults of cultured Caspian shemaya were captured from Anzali Wetland by gill nets and after biometry were transferred to the laboratory for histological examination, plasma sex steroid assays and determination of reproductive indices. Totally, 42 females and 16 males were captured during March to May 2014 by gill net and divided into two age groups including 2 years old and 3 years old. The age determination was done by taking the scale samples from each fish and counting the number of annuli (rings) on each scale (Nikolsky, 1963). In each age group, fish were classified into two groups including matured and maturing fish depending on the maturation stage. In this regard, in matured fish, eggs and spermatozoa were released with little pressure of belly while in maturing fish the belly

was hard and releasing of eggs and spermatozoa was not observed.

Reproductive indices

Oocyte diameter was measured by a scaled loupe. Absolute fecundity, hepatosomatic index (%HSI) and gonadosomatic index (%GSI) were calculated according to the following formulae:

Absolute fecundity= $(n \times G) / g$ (Tyler *et al.*, 1996; Brown-Peterson, 2011)

Where n, G and g refer to number of oocytes in sampled ovary, weight of ovary and weight of sampled ovary, respectively.

% HSI= $LW / BW \times 100$ (Hajirezaee *et al.*, 2012)

Where LW and BW refer to weight of liver and body, respectively.

% GSI= $GW / BW \times 100$

Where GW and BW refer to weight of gonad and body, respectively.

Blood sampling

The blood samples were collected monthly by cutting of caudal peduncle and centrifuged (13,700g for 10 min) to separate the serum and was stored at -20°C until hormonal analysis.

Steroid assays

All steroids including P, T and E2 were assessed by ELISA method using commercial assay kits according to Bayunova *et al.* (2002). Assay kits were obtained from SPECTERIA, Finland.

Gonads histology

Ovaries and testes of collected fish were fixed in Bouin's solution,

embedded in paraffin, serially sectioned at 6 μ m, and stained with hematoxylin according to Mousavi-Sabet *et al.* (2012). Prepared slides of ovaries and testes were investigated using a light microscope at $\times 200$ magnification.

Statistical analysis

All data were analyzed by SPSS software (Version 16). Normality of data was examined by Shapiro-Wilk test. One-way analysis of variance (ANOVA) was employed to compare the means. When significant F-ratios were calculated by ANOVA, the Tukey test was applied to identify which means were different.

Results

There were no significant differences between matured and maturing males and females in terms of absolute fecundity (Table 1, $p > 0.05$). In each age group, oocyte diameter was higher in matured fish than in maturing individuals (Table 1, $p < 0.05$). In 2 years old males and In 3 years old females, higher HSI values were recorded for maturing fish compared to matured fish (Table 2, $p < 0.05$). In females, the plasma levels of E2, T as well as P were significantly higher and lower in maturing fish and matured individuals, respectively (Table 3, $p < 0.05$).

Table 1: Comparison of absolute fecundity and oocyte diameter (μm) between male and females of *Alburnus chalcoides* with different age and gonad maturation stage. The statistical differences are shown by different letters ($p<0.05$). Female (2+): 2 years old females; female (3+): 3 years old females.

Absolute fecundity				Oocyte diameter			
Female (2+)		Female (3+)		Female (2+)		Female (3+)	
Matured	Maturing	Matured	Maturing	Matured	Maturing	Matured	Maturing
7467.23 \pm	8055.01 \pm	568.01 \pm	987.18 \pm	774.21 \pm	599.42 \pm	806.6 \pm	695.9 \pm
989.39 ^a	643.21 ^a	1.03 ^a	1.22 ^a	22.03 ^a	21 ^b	17.94 ^a	17 ^b

Table 2: Comparison of hepatosomatic index (% HSI) and gonadosomatic index (% GSI) between male and females of *Alburnus chalcoides* with different age and gonad maturation stage. The statistical differences are shown by different letters ($p<0.05$). Male (3+): 3 years old males; female (2+): 2 years old females; female (3+): 3 years old females.

HSI							
Male (2+)		Male (3+)		Female (2+)		Female (3+)	
Matured	Maturing	Matured	Maturing	Matured	Maturing	Matured	Maturing
0.48 \pm	2.02 \pm	0.51 \pm	1.7 \pm	0.89 \pm	0.9 \pm	0.6 \pm	0.92 \pm
0.06 ^a	1.17 ^b	0.02 ^a	1.2 ^b	0.22 ^a	0.11 ^a	0.08 ^b	0.12 ^a
GSI							
8.35 \pm	6.36 \pm	10.1 \pm	7.2 \pm	15.64 \pm	14.53 \pm	15.5 \pm	12.50 \pm
0.41 ^a	0.92 ^b	0.3 ^a	0.2 ^b	0.6 ^a	0.44 ^b	0.3 ^a	0.44 ^b

Table 3: Comparison of serum sex steroids between male and females of *Alburnus chalcoides* with different age and gonad maturation stage. The statistical differences are shown by different letters ($p<0.05$). Male (3+): 3 years old males; female (2+): 2 years old females; female (3+): 3 years old females.

Steroids (ng/mL)	Male		Female	
	Matured	Maturing	Matured	Maturing
Progesterone	0.38 \pm 0.04 ^a	0.36 \pm 0.04 ^a	0.36 \pm 0.04 ^a	0.25 \pm 0.03 ^b
Estradiol-17 β	2.87 \pm 0.33 ^a	2.27 \pm 0.44 ^a	2.55 \pm 0.09 ^a	2.98 \pm 0.18 ^b
Testosterone	12.13 \pm 0.68 ^a	8.77 \pm 0.55 ^b	3.88 \pm 1.12 ^a	7.93 \pm 1.19 ^b

In males, only plasma T was higher in matured fish compared to maturing fish ($p<0.05$) and other assayed steroids did not show significant differences (Table 3, $p<0.05$). Also, histological examination of gonads from 10 males and females showed that all fish were in the final maturation stages. In the examined fish the following gonadal stages were observed: (a) in matured females: dormant stage oocytes, germinal vesicle stage, hydrated

oocytes (Fig. 1a). (b) In maturing females: dormant stage oocytes, germinal vesicle stage, hydrated oocytes (Fig. 1b). (c) In matured males: spermatid and mainly spermatozoa (Fig. 1c). (d) In maturing males: spermatid and spermatozoa (Fig. 1d).

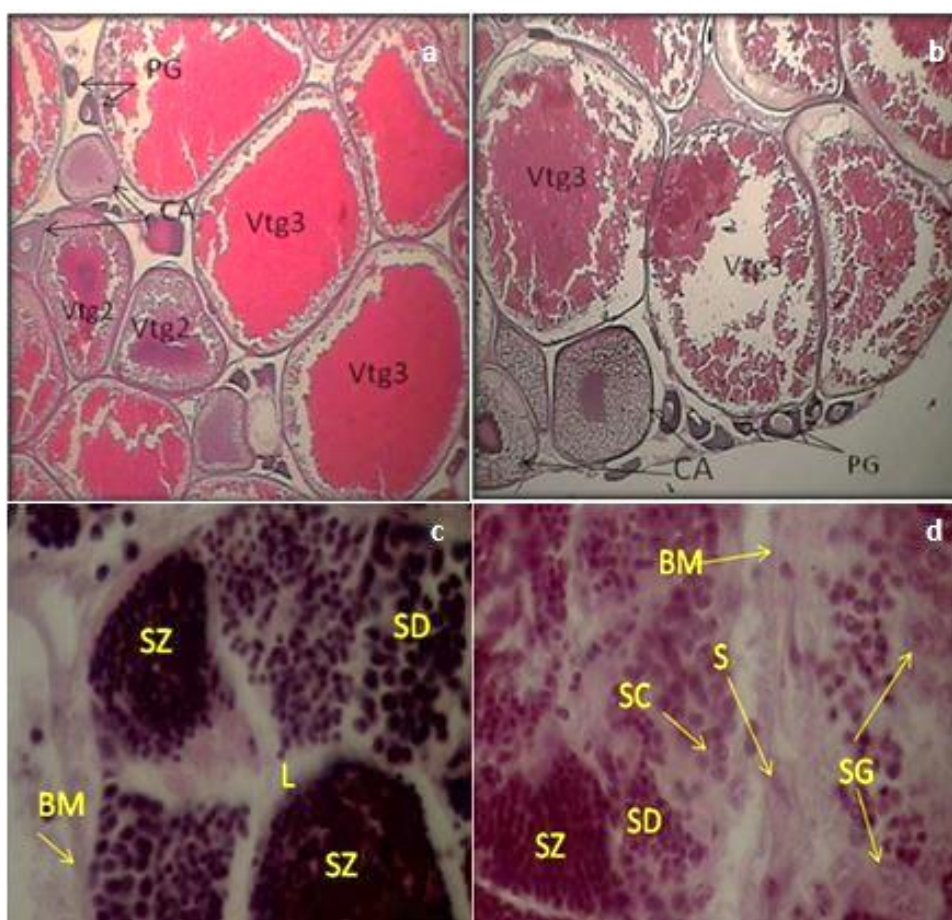


Figure 1: Cross section of ovary and testis of Caspian shemaya in mated and maturing fish. (a) Mated female. PG: Primary growth oocyte, Vtg3: Tertiary vitellogenesis stage, Vtg2: Secondary vitellogenesis stage, CA: Cortical alveolar oocytes, (b) Maturing female. PG: Primary growth oocyte, Vtg3: Tertiary vitellogenesis stage, Vtg2: Secondary vitellogenesis stage, CA: Cortical alveolar oocytes. (c) Mated male. SZ: Spermatozoa, SD: Spermatid, L: Lydic cell, BM: Basement membrane. (d) Maturing male. SZ: Spermatozoa, SD: Spermatid, SC: Spermatocyte, SG: Spermatogonia. HE×40.

Discussion

In the present study, two groups of Caspian shemaya adults from Anzali Wetland including mated and maturing fish were investigated in order to determine their reproductive status. Based on histological examinations of ovaries and testes and plasma levels of sex steroids, the maturing group was in the pre-spawning stage and we did not observe any egg or spermatozoa ejaculation by applying pressure to the

belly. In mated shemaya, although we recorded the release of eggs or spermatozoa by applying a gentle hand pressure on the abdomen, some indices of pre-spawning stages were observed in our histological observations. These results show that Caspian shemaya is probably a multiple spawner with a protracted spawning period (Nikoo *et al.*, 2010). According to results of steroid assay, we found higher plasma concentrations of E2, T and P in

matured males and females of Caspian shemaya compared to that in maturing fish. T is the predominant androgen in male teleosts and plays an important role in spermatogenesis as a precursor of 11-KT (Hajirezaee *et al.*, 2012). In female teleosts, it was suggested that T could be involved in formation of oil droplets in oocytes and stimulation of follicle stimulating hormone (FSH) involved in vitellogenesis (Hajirezaee *et al.*, 2012). On the other hand, it was recognised that T can act as a precursor of E2 in follicular layers. In females, E2 stimulates the liver production of vitellogenin (VTG). VTG is subsequently sequestered by the oocytes, processed and stored for the nutrition of the embryo (Reviewed by Lubzens *et al.*, 2010). The P hormone is usually predominant in female teleosts and acts as a precursor of other steroids in the steroidogenic pathways (Manire and Rasmussen, 1997; Gelsleichter, 2004; Henningsen *et al.*, 2008, Ahmadnezhad *et al.*, 2013, Jamalzadeh *et al.*, 2012). In our study, the higher levels of sex steroids in matured fish compared to maturing fish may be due to the multiple spawning pattern of reproduction in Caspian shemaya and the development of the initial stages of maturation in parts of the ovary and testis. In the present study, the values of HSI and GSI were higher in matured males and females compared to that in maturing individuals. Higher GSI values in matured fish show that gonads are more developed in them compared to maturing fish (Hajirezaee *et al.*, 2012). This was confirmed when we

recorded higher absolute fecundity and oocyte diameter in matured Caspian shemaya compared to maturing fish. Also, higher HSI in matured fish than in maturing fish may be due to raised liver function and synthesis of vitellogenin (Banaee and Naderi, 2014). In conclusion, the results of the present study indicate that most Caspian shemaya are in the pre-spawning stage and even more developed (certainly in matured fish). Therefore, during this period of time the adults of Caspian shemaya could be captured and transferred to hatcheries for artificial control of reproduction.

References

- Ahmadnezhad, M., Oryan, Sh., Hosseinzadeh Sahafi, H., Khara H., 2013.** Effect of synthetic luteinizing hormone - releasing hormone (LHRH-A2) plus pimozone and chlorpromazine on ovarian development and levels of gonad steroid hormones in female kutum *Rutilus frisii kutum*. *Turkish Journal of Fisheries and Aquatic Sciences*, 13, 95-100.
- Banaee, M. and Naderi M., 2014.** The reproductive biology of shirbot (*Barbus grypus* Heckel, 1843) in the Maroon River, Iran. *International Journal of Aquatic Biology*, 2, 43-52.
- Bayunova, L., Barannikova, I., Semenkova, T., 2002.** Sturgeon stress reactions in aquaculture. *Journal of Applied Ichthyology*, 18, 397-404.

- Brown-Peterson, N.J., Wyanski, D.M., Saborido-Rey, F., Macewicz, B.J. and Lowerre-Barbieri, S.K., 2011.** A standardized terminology for describing reproductive development in fishes. *American Fisheries Society*, 3, 52–70.
- Falahatkar, B., Amlashi, A.S., Eagderi, S. and Mousavi-Sabet, H., 2015.** Review on the Caspian shemaya, *Alburnus chalcoides* (Güldenstädt, 1772). *International Journal of Aquatic Biology*, 3(5), pp. 323-330.
- Gelsleichter, J., 2004.** Hormonal regulation of elasmobranch physiology. In: Carrier JC, Musick JA, Heithaus MR, editors. *Biology of sharks and their relatives*. Boca Raton: CRC Press. pp. 287-324.
- Hajirezaee, S., Amiri, B.M., Mehrpoosh, M., Jafaryan, H., Mirrasuli, E. and Golpour, A., 2012.** Gonadal development and associated changes in gonadosomatic index and sex steroids during the reproductive cycle of cultured male and female Caspian brown trout, *Salmo trutta caspius* (Kessler, 1877). *Journal of Applied Animal Research*, 40, 154-162
- Henningsen, A.D., Murru, F.L., Rasmussen, L.E.L., Whitaker, B.R. and Violetta, G.C., 2008.** Serum levels of reproductive steroid hormones in captive Sandtiger sharks, *Carcharias taurus* (Rafinesque), and comments on their relation to sexual conflicts. *Fish Physiology Biochemistry*, 34, 437-446.
- Jamalzadeh, H.R., Hajirezaee, S., Nazeri, S., Khara, H., Mirrasuli, E., 2012.** Identification of follicular vitellogenesis stage by monitoring calcium and estradiol-17 β concentrations in the cultured Caspian brown trout, *Salmo trutta caspius* Kessler, 1877. *Biologia*. 67(4), 796-799.
- Kiabi, B.H., Abdoli, A. and Naderi, M., 1999.** Status of the fish fauna in the South Caspian Basin of Iran. *Zoology in the Middle East*, 18, 57–65.
- Lubzens, E., Young, G., Bobe, J. and Cerdà, J., 2010.** Oogenesis in teleosts: how fish eggs are formed. *General and Comparative Endocrinology*, 165(3), 367-389.
- Manire, C.A. and Rasmussen, L.E.L., 1997.** Serum concentrations of steroid hormones in the mature male bonnethead shark, *Sphyrna tiburo*. *General and Comparative Endocrinology*, 107, 414-420.
- Mostafavi, H., 2007.** Fish biodiversity in Talar River, Mazandaran Province. *Journal of Environmental Studies*, 32, 127-135.
- Mousavi-Sabet, H., Kamali, A., Soltani, M., Bani, A., Esmaili, H.R., Khoshbavar Rostami, H., Vatandoust, S. and Moradkhani, Z., 2012.** Reproductive biology of *Cobitis keyvani* (Cobitidae) from the Talar River in the southern Caspian Sea basin. *Iranian Journal of Fisheries Sciences*, 11(2), 383-393.
- Mylonas, C.C., Fostier, A. and Zanuy, S., 2010.** Broodstock management and hormonal

manipulations of fish reproduction. *General and Comparative Endocrinology*, 165(3), 516-534.

Naderi, J.M., Abdoli, A., 2004. Fish Species Atlas of South Caspian Sea Basin (Iranian Waters). Iranian Fisheries Research Organization, Tehran (In Persian.). 80P.

Nikoo, M., Rahmani, H., Ghomi, M.R., Asadollahpour, A., Zarei, M., Bavand, E., 2010. Serum sex steroid hormones (testosterone, 17 β -estradiol and progesterone) of Caspian vimba, *Vimba vimba* and Shemaya, *Alburnus chalcoides* during spawning period, *Iranian Journal of Natural Resources*, 63(1), 49-56.

Nikolsky, G.V., 1963. The ecology of fishes. Academic, London, 352P.

Poulin, R., 1998. Evolutionary ecology of parasites: from individuals to communities. Chapman and Hall, London, 212P.

Tarkan, A.S., Gaygusuz, O., Acipinar, H. and GURSOY, C., 2005. Characteristics of a Eurasian cyprinid, shemaya, *Chalcalburnus chalcoides* (Guldenstadt, 1772), in a mesotrophic water. *Zoology in the Middle East*, 35, 49-60.

Tyler, C.R., Pottinger, T.G., Santos, E., Sumpter, J.P., Price, S-A., Brooks, S. and Nagler, J.J., 1996. Mechanisms controlling egg size and number in the rainbow trout, *Oncorhynchus mykiss*. *Biology of Reproduction*, 54, 8-15.