

Occurrence of squamous cell carcinoma in a platy fish (*Xiphophorus maculatus*): A case report

Rezaie A.¹; Tulaby Dezfuly Z.^{2*}; Peyghan R.²

1- Department of Pathobiology, Faculty of Veterinary Medicine, Shahid Chamran University of Ahvaz, Ahvaz, Iran.

2-Department of Clinical Sciences, Faculty of Veterinary Medicine, Shahid Chamran University of Ahvaz, Ahvaz, Iran.

*Corresponding author's Email: z.tulaby@gmail.com

Keywords: Platy fish, *Xiphophorus maculatus*, Squamous cell carcinoma, Histopathology

Introduction

According to prior reports, similar to mammals, fish are frequently affected by neoplastic proliferations. These neoplasms are classified according to the mammalian tumor classification System (Rahmati-Holasoo *et al.*, 2010). Squamous cell carcinoma (SCC) is one of the most common forms of skin neoplasm in which cells in the epithelial layer of the skin develop into a malignant tumor. SCC has been reported in both fresh and marine water fish (Mawdesley-Thomas and Bucke, 1967) Squamous cell carcinoma has been reported in a number of species, for example, Atlantic salmon, *Salmo salar* L. (Roberts, 1972); oscar, *Astronotus ocellatus* (Rahmati-Holasoo *et al.*, 2010); rudd, *Scardinius erythrophthalmus* (Hanjavanit and Mulcahy, 2004); gudgeon, *Gobio gobio*

(Mawdesley-Thomas and Bucke, 1967); gulf menhaden, *Brevoortia patronus* Goode (Fournie *et al.*, 1987); and the hybrid sunfish (Fitzgerald *et al.*, 1991). In spite of the fact that reports have been previously published on SCC in various species of fish, to the best of the author's knowledge, this is the first report on SCC in platy fish (*Xiphophorus maculatus*) in the world.

Materials and methods

In the summer of 2015, a one-year-old platy fish, 4 cm in length and 4.5 g in weigh, was delivered to the laboratory of aquatic animal health in the Veterinary Faculty (Shahid Chamran University of Ahvaz). The fish was delivered with a large black mass (0.5×0.8cm) on the left side of the body. The owner stated that the mass appeared in the mentioned region about

4 months ago and increased gradually in size with time. The fish was anesthetized with 2- phenoxy ethanol and the mass removed surgically. The samples were taken from the mass and surrounding tissues and fixed in 10% phosphate-buffered formalin for 2 weeks. Specimens were processed as routine and stained with Hematoxylin and Eosin (Rahmati-Holasoo *et al.*, 2010). In the present study, histopathological analyses were conducted and the type of the tumor identified.

Results and discussion

Gross lesions manifested as distinct amorphous dark black, with tan or brown mottled areas (Fig. 1). The skin lesion covered a significant area of the fish surface, and there was no predilection for lesions affecting another particular part of the fish.

Microscopic examination of the mass revealed multiple round islets of keratinocytes in the dermis. The size of nodules was different and the cell layers were varied (Figs. 2 and 3). Pleomorphism and mitotic figures were obvious. Keratinocytes in the outer layers of islets were spindle-shaped and cells in the center were large and the nuclei were vesicular with clear nucleoli. Some of the keratinocytes in the center were necrotic and they had dark blue nuclei with eosinophilic cytoplasm (Fig. 4). Also, some of them were desquamated in the center of nodules. The nests of cells were surrounded by connective tissue and

inflammatory cells. According to microscopic characteristics, squamous cell carcinoma was diagnosed.

The classification was done according to Goldschmidt *et al.* (1998). In this method, five grades were assumed as follows: carcinoma in situ (G0), well differentiated (G1), moderately differentiated (G2), poorly differentiated (G3) and anaplastic (G4) carcinoma. Based on mentioned characteristics, it was classified as moderately differentiated (G2).

Squamous cell carcinoma (SCC) originated from squamous cells in the upper part of the epidermis (Hanjavanit and Mulcahy, 2004). Fish neoplasm has recently received considerable emphasis as an early warning system for detection of carcinogens in the aquatic environment. Skin cancer exemplifies gathering of genetic abnormalities, inherent and/or sporadic, that modify the cells in such a way that normal function is damaged and a tumor arises (Byankin, 2001). Squamous cell carcinomas have been reported less than papillomas, but do occur in a wide range of fish species mainly, on the lips, oral mucosa, mandible, olfactory organ etc. (Byankin, 2001; Rahmati-Holasoo *et al.*, 2010).

Classification in Goldschmidt *et al.* (1998) methods were evaluated based on the presence and intensity of keratinization, squamous differentiation and island development of neoplastic cells and invasiveness.



Figure 1: Platy fish (*Xiphophorus maculatus*). Note the large black mass on the left side of the body.

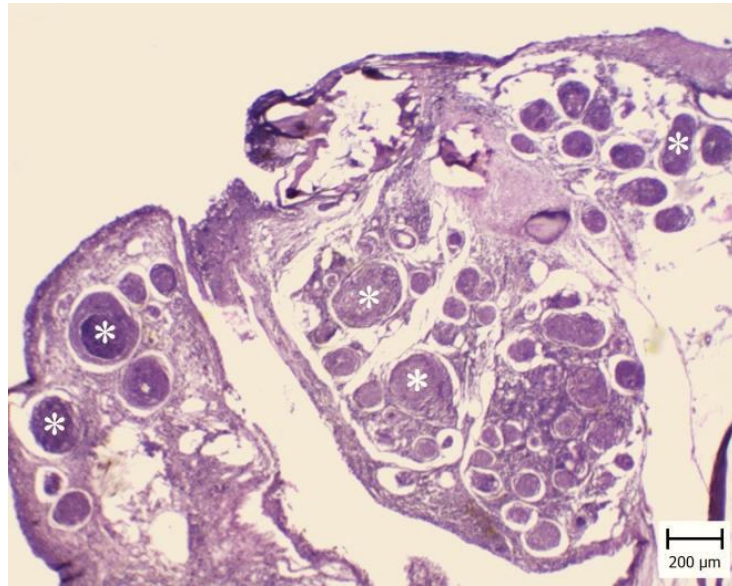


Figure 2: Squamous cell carcinoma in the skin of platy fish (*Xiphophorus maculatus*). Note multiple round islets (asterisks) with different size beneath the epidermis (H & E).

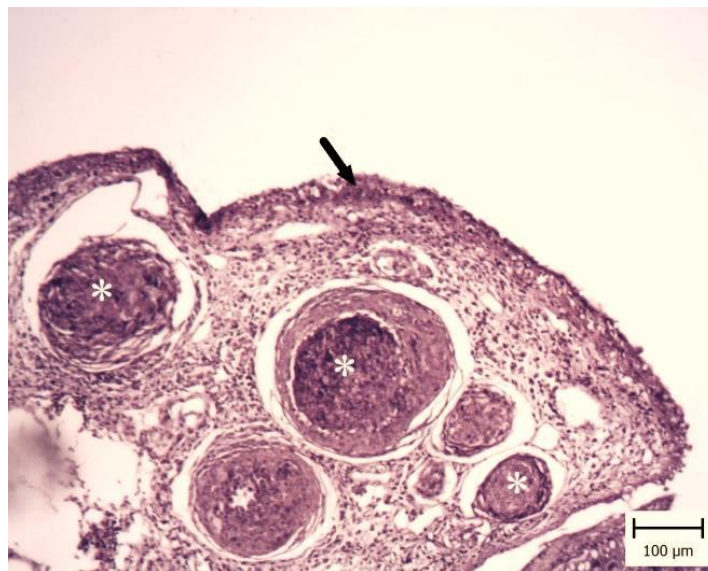


Figure 3: Squamous cell carcinoma in skin. Platy fish (*Xiphophorus maculatus*). Part of fig. 2 with higher magnification. Five round islets (asterisks) with different size beneath the epidermis (arrow) are obvious (H & E).

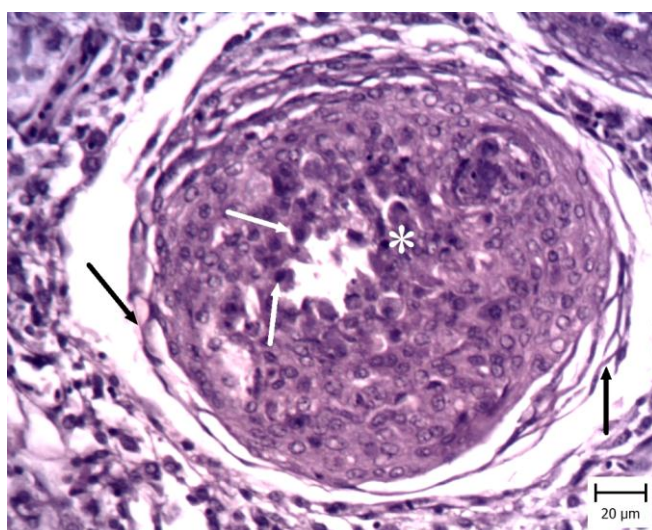


Figure 4: Squamous cell carcinoma in the skin of platy fish (*Xiphophorus maculatus*). The islet is surrounded by connective tissue (black arrows). Keratinocytes are large and pleomorphic. They had vesicular nuclei with obvious nucleoli. In the center, most of the cells are necrotic (asterisk) and they had pyknotic (white arrows) nuclei (H & E).

The G₂ was attributed to moderately differentiated neoplasms with a moderate degree of keratinization and differentiation with an increased number of poorly differentiated cells, demonstrating small- to medium-sized keratin pearls and nests, and the small islands of invasive or noninvasive neoplastic cells surrounding the main tumor. The clinical manifestation of fish with no metastases was regarded as moderate malignancy of the tumor.

The etiology of this malignant tumor is not entirely clear, but a viral agent has been suggested for SCC in some fishes, for example, rainbow smelt, *Osmerus mordax* (Herman, 1988; Morrison *et al.*, 1996), and common carp, *Cyprinus carpio* L. (Sano *et al.*, 1985). Retroviruses and picornaviruses are suggested as possible agents in the etiology of SCC in walleye, *Stizostedion vitreum* (Mitchill), and

European smelt, *Osmerus eperlanus* (L.), respectively (Walker, 1969; Ahne *et al.*, 1990). In the present study, no viral test was conducted, and it is possible that a viral agent could cause SCC in platy fish that needs to be evaluated in future studies.

In conclusion, macroscopic and microscopic characteristics of squamous cell carcinoma was described in a platy fish (*X. maculatus*) for the first time. Also, grading was performed and it was moderately differentiated.

Acknowledgements

This work was financially supported by the research council of Shahid Chamran University, Ahvaz, Iran.

References

Ahne, W., Anders, K., Halder, M. and Yoshimizu, M., 1990. Isolation of picornavirus-like particles from

- the European smelt, *Osmerus eperlanus* (L.). *Journal of Fish Diseases*, 13, 167–168.
- Byankin, A.G., 2001.** Tumour like formations in the olfactory organ of the striped mullet, *Mugil cephalus* from Sovetskaya Gavan' bay, sea of Japan. *Russian Journal of Marine Biology*, 27, 333–335.
- Fitzgerald, S.D., Carlton, W.W. and Sandusky, G., 1991.** Metastatic squamous cell carcinoma in a hybrid sunfish. *Journal of Fish Diseases*, 14, 481–488.
- Fournie, J.W., Vogelbein, W.K. and Overstreet, R.M., 1987.** Squamous cell carcinoma in the gulf menhaden, *Brevoortia patronus* Goode. *Journal of Fish Diseases*, 10, 133–136.
- Goldschmidt, M.H., R.W. Dunstan, A.A. Stannard, C. Von Tsharner, E.J. Walder and J.A., 1998.** Histological classification of epithelial and melanocytic tumors of the skin of domestic animals. 2nd ed., Vol. 3, World Health Organization, Washington, DC, pp. 20-21.
- Hanjavanit, C. and Mulcahy, M.I.F., 2004.** Squamous cell carcinoma in rudd *Scardinius erythrophthalmus*: histopathology, ultrastructure, and transmission. *Diseases of Aquatic Organisms*, 61, 215–226.
- Herman, R.L. 1988.** Squamous cell carcinoma in rainbow smelt *Osmerus mordax*. *Diseases of Aquatic Organisms*, 5, 71–73.
- Mawdesley-Thomas, L.E. and Bucke, D., 1967.** Squamous cell carcinoma in a gudgeon (*Gobio gobio*, L.). *Pathologia Veterinaria*, 4, 484–489.
- Morrison, C.M., Leggiadro, C.T. and Martell, D.J., 1996.** Visualisation of viruses in tumors of rainbow smelt *Osmerus mordax*. *Diseases of Aquatic Organisms*, 26, 19–23.
- Rahmati-Holasoo, H., Hobbenaghi, R., Tukmechi, A. and Morvaridi, A., 2010.** The case report on squamous cell carcinoma in Oscar (*Astronauts ocelots*). *Comparative Clinical Pathology*, 19, 421–424.
- Roberts, R.J., 1972.** Oral carcinomata in a salmon (*Salmo salar* L.). *Veterinary Record*, 91, 199.
- Sano, T., Fukuda, H. and Furukawa, M. 1985.** Herpesvirus cyprini: biologic and oncogenic properties. *Fish Pathology*, 20, 381–388.
- Walker, R. 1969.** Virus associated with epidermal hyperplasia in fish. In: Neoplasms and related disorders of invertebrate and lower vertebrate animals (ed. by C.J. Dawe and J.C. Harshbarger), National Cancer Institute Monograph, Washington, DC, pp. 195–208.